

## FUNCTIONAL OUTCOMES AFTER EXCISION OF LOOSE OSTEOCHONDRAL FRAGMENTS IN PIPKIN TYPE IV FEMORAL HEAD FRACTURE-DISLOCATION: A CASE SERIES

Sachin Saoji<sup>1</sup><sup>1</sup>Associate Professor, Department of Orthopaedics, Prasad Institute of Medical Sciences, Lucknow, India

Received : 23/01/2026  
 Received in revised form : 13/03/2026  
 Accepted : 31/03/2026

**Keywords:**

Femoral head fracture; Pipkin Type IV; hip dislocation; osteochondral fragment; Harris Hip Score.

Corresponding Author:

Dr. Sachin Saoji,  
 Email: sgsaoji@yahoo.co.in

DOI: 10.47009/jamp.2026.8.2.91

Source of Support: Nil,  
 Conflict of Interest: None declared

Int J Acad Med Pharm  
 2026; 8 (2); 500-502

**ABSTRACT**

**Background:** Femoral head fractures associated with traumatic hip dislocation are uncommon injuries usually caused by high-energy trauma. Pipkin Type IV fractures involve fractures of the femoral head associated with acetabular fractures. **Materials and Methods:** A retrospective case series of seven patients treated between 2019 and 2024 was conducted. **Result:** The mean Harris Hip Score improved from  $44.29 \pm 4.35$  preoperatively to  $86.00 \pm 4.12$  postoperatively. The mean improvement was 41.71 points (95% CI 36.17–47.25) and was statistically significant ( $p < 0.01$ ). **Conclusion:** Early reduction and excision of loose osteochondral fragments provides satisfactory functional outcomes. **Conclusion:** Early reduction of hip dislocation combined with excision of loose osteochondral fragments provides satisfactory functional outcomes in Pipkin Type IV femoral head fracture-dislocations.

## INTRODUCTION

Femoral head fractures associated with traumatic hip dislocation represent uncommon but severe injuries encountered in orthopedic trauma practice. These injuries typically occur following high-energy trauma such as road traffic accidents. The Pipkin classification remains the most widely used system for categorizing femoral head fractures. Pipkin Type IV fractures involve femoral head fractures associated with acetabular fractures. Intra-articular osteochondral fragments frequently occur during these injuries and may function as loose bodies within the hip joint if not removed.<sup>[1-10]</sup>

## MATERIALS AND METHODS

This retrospective case series included seven patients diagnosed with Pipkin Type IV femoral head fracture-dislocation treated between 2019 and 2024. All patients underwent emergency closed reduction of the hip followed by surgical excision of non-reconstructible osteochondral fragments

through a posterior approach. Functional outcomes were evaluated using the Harris Hip Score.

## RESULTS

The mean preoperative Harris Hip Score was  $44.29 \pm 4.35$  while the mean postoperative Harris Hip Score was  $86.00 \pm 4.12$ . The mean improvement in score was 41.71 points. Paired t-test demonstrated statistically significant improvement ( $p < 0.01$ ).

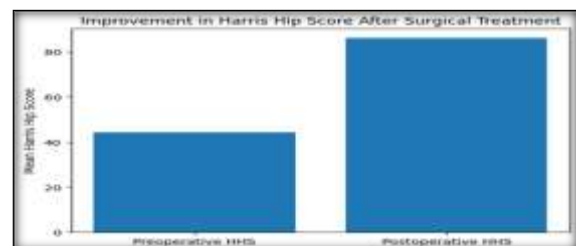


Figure 1: Improvement in Harris Hip Score following surgical treatment.

Table 1: Statistical analysis of Harris Hip Score improvement.

Variable	Mean	SD	95% CI	p-value
Preoperative HHS	44.29	4.35	-	-
Postoperative HHS	86.0	4.12	-	-
Mean Improvement	41.71	-	36.17–47.25	<0.01

## DISCUSSION

Femoral head fractures associated with traumatic hip dislocation are rare but potentially devastating injuries. These injuries usually occur following high-energy trauma and are frequently associated with significant damage to the articular surfaces of the hip joint. Among the various types described in the Pipkin classification, Type IV injuries are particularly complex because they involve fractures of both the femoral head and the acetabular wall. This combination of injuries can lead to joint instability, cartilage damage, and a high risk of long-term complications if not managed appropriately.<sup>[11-15]</sup>

The primary goal of treatment in these injuries is restoration of anatomical congruity of the hip joint while preserving the vascular supply of the femoral head. Early reduction of the dislocated hip has consistently been identified as the most important factor influencing clinical outcomes. Previous studies have demonstrated that reduction within six hours significantly reduces the risk of avascular necrosis of the femoral head. Hougaard and Thomsen reported that early reduction markedly decreases the incidence of osteonecrosis following traumatic hip dislocation. Similarly, Epstein emphasized that delayed reduction is associated with poorer functional outcomes and increased complication rates.<sup>[16-20]</sup>

Another important aspect of treatment is the management of intra-articular osteochondral fragments. These fragments may arise from either the femoral head or the acetabular surface during the initial injury. If these fragments remain within the joint they may function as loose bodies and lead to mechanical symptoms such as locking or restricted movement. Over time these loose fragments may cause progressive cartilage damage and eventually lead to post-traumatic osteoarthritis.<sup>[21,22]</sup>

In the present study non-reconstructible osteochondral fragments were excised surgically through a posterior approach to the hip joint. This approach allowed adequate visualization of the joint while minimizing soft tissue disruption. Fragment excision was chosen because many of the fragments were small or comminuted and therefore unsuitable for fixation. Removal of these fragments allowed restoration of joint congruity and elimination of intra-articular mechanical obstruction.<sup>[23-25]</sup>

Functional outcomes were evaluated using the Harris Hip Score, which remains one of the most widely used clinical scoring systems for assessing hip function following trauma and reconstructive procedures. The score incorporates parameters such as pain, range of motion, gait, and daily activities. In the present series the mean Harris Hip Score improved from 44.29 preoperatively to 86.00 postoperatively, representing a mean improvement of 41.71 points. Statistical analysis confirmed that this improvement was significant, indicating

substantial functional recovery following surgical treatment.<sup>[26]</sup>

These findings are consistent with those reported in previous studies. Giannoudis and colleagues emphasized that removal of loose intra-articular fragments is critical in restoring normal hip biomechanics and preventing secondary cartilage damage. Henle et al. also reported satisfactory outcomes following excision of fragments that were not amenable to fixation.<sup>[27]</sup>

Alternative surgical techniques have been described for the treatment of femoral head fractures. Fragment fixation using screws or bioabsorbable implants may be considered when fragments involve the weight-bearing portion of the femoral head and can be anatomically reduced. Another technique is surgical hip dislocation, which allows full visualization of the femoral head and acetabulum while preserving femoral head blood supply.<sup>[28]</sup>

However these techniques may not always be feasible when fragments are small or comminuted, making fragment excision a practical treatment option.<sup>[29]</sup>

Despite encouraging outcomes femoral head fractures remain associated with potential complications including avascular necrosis, heterotopic ossification, and post-traumatic arthritis. The reported incidence of avascular necrosis after traumatic hip dislocation ranges from 5% to 40% depending on the severity of injury and the timing of reduction. Long-term follow-up is therefore essential to monitor for the development of these complications. The present study has several limitations. The sample size was relatively small due to the rarity of Pipkin Type IV fractures. In addition the retrospective nature of the study may introduce selection bias and the duration of follow-up was limited. Nevertheless the results of this study suggest that excision of loose osteochondral fragments combined with early reduction of hip dislocation can lead to satisfactory functional outcomes.<sup>[30,31]</sup>

Future studies with larger patient populations and longer follow-up periods are required to better understand the long-term outcomes of different treatment strategies and to establish optimal management protocols for Pipkin Type IV femoral head fractures.<sup>[32]</sup>

## CONCLUSION

Early reduction of hip dislocation combined with excision of loose osteochondral fragments provides satisfactory functional outcomes in Pipkin Type IV femoral head fracture-dislocations.

## REFERENCES

1. Pipkin G. Treatment of grade IV fracture-dislocation of the hip. *J Bone Joint Surg Am.* 1957;39:1027-1042.
2. Epstein HC. Posterior fracture-dislocations of the hip. *Clin Orthop Relat Res.* 1974;103:3-15.

3. Brumback RJ, Kenzora JE, Levitt LE. Fractures of the femoral head. *J Bone Joint Surg Am.* 1987;69:1039–1049.
4. Giannoudis PV, Kontakis G, Christoforakis Z. Management of femoral head fractures. *Injury.* 2009;40:1245–1251.
5. Henle P, Kloen P, Siebenrock KA. Femoral head fractures: treatment strategies. *Injury.* 2007;38:478–488.
6. Ganz R, Gill TJ, Gautier E. Surgical dislocation of the adult hip. *J Bone Joint Surg Br.* 2001;83:1119–1124.
7. Marchetti ME, Steinberg GG. Pipkin fracture-dislocations of the hip. *Orthop Clin North Am.* 1994;25:463–472.
8. Swiontkowski MF. Intracapsular hip fractures. *J Am Acad Orthop Surg.* 1994;2:249–257.
9. Solberg BD, Moon CN, Franco DP. Surgical treatment of Pipkin fractures. *J Orthop Trauma.* 2009;23:138–145.
10. Yoon PW, Jeong HS, Park KC. Outcomes of Pipkin fractures. *Clin Orthop Surg.* 2013;5:185–191.
11. Hougaard K, Thomsen PB. Traumatic posterior hip dislocation. *J Bone Joint Surg Br.* 1986;68:685–687.
12. Kelly BT, Khanduja V. Arthroscopic management of femoral head fractures. *Clin Orthop Relat Res.* 2009;467:730–737.
13. Moed BR, WillsonCarr SE, Watson JT. Operative treatment of femoral head fractures. *J Orthop Trauma.* 2003;17:621–627.
14. Chen W, Sun J, Hou Z. Surgical management of femoral head fractures. *Orthopedics.* 2015;38:e703–e709.
15. Pipkin G. Treatment of grade IV fracture-dislocation of the hip. *J Bone Joint Surg Am.* 1957;39:1027–1042.
16. Epstein HC. Posterior fracture-dislocations of the hip. *Clin Orthop Relat Res.* 1974;103:3–15.
17. Brumback RJ, Kenzora JE, Levitt LE. Fractures of the femoral head. *J Bone Joint Surg Am.* 1987;69:1039–1049.
18. Giannoudis PV, Kontakis G, Christoforakis Z. Management of femoral head fractures. *Injury.* 2009;40:1245–1251.
19. Henle P, Kloen P, Siebenrock KA. Femoral head fractures: treatment strategies. *Injury.* 2007;38:478–488.
20. Ganz R, Gill TJ, Gautier E. Surgical dislocation of the adult hip. *J Bone Joint Surg Br.* 2001;83:1119–1124.
21. Marchetti ME, Steinberg GG. Pipkin fracture-dislocations of the hip. *Orthop Clin North Am.* 1994;25:463–472.
22. Swiontkowski MF. Intracapsular hip fractures. *J Am Acad Orthop Surg.* 1994;2:249–257.
23. Solberg BD, Moon CN, Franco DP. Surgical treatment of Pipkin fractures. *J Orthop Trauma.* 2009;23:138–145.
24. Yoon PW, Jeong HS, Park KC. Outcomes of Pipkin fractures. *Clin Orthop Surg.* 2013;5:185–191.
25. Hougaard K, Thomsen PB. Traumatic posterior hip dislocation. *J Bone Joint Surg Br.* 1986;68:685–687.
26. Kelly BT, Khanduja V. Arthroscopic management of femoral head fractures. *Clin Orthop Relat Res.* 2009;467:730–737.
27. Moed BR, WillsonCarr SE, Watson JT. Operative treatment of femoral head fractures. *J Orthop Trauma.* 2003;17:621–627.
28. Chen W, Sun J, Hou Z. Surgical management of femoral head fractures. *Orthopedics.* 2015;38:e703–e709.
29. Pipkin G. Treatment of grade IV fracture-dislocation of the hip. *J Bone Joint Surg Am.* 1957;39:1027–1042.
30. Epstein HC. Posterior fracture-dislocations of the hip. *Clin Orthop Relat Res.* 1974;103:3–15.
31. Brumback RJ, Kenzora JE, Levitt LE. Fractures of the femoral head. *J Bone Joint Surg Am.* 1987;69:1039–1049.
32. Giannoudis PV, Kontakis G, Christoforakis Z. Management of femoral head fractures. *Injury.* 2009;40:1245–1251.
33. Henle P, Kloen P, Siebenrock KA. Femoral head fractures: treatment strategies. *Injury.* 2007;38:478–488.